

# Significance of Disinfectants for the Treatment of Atopic Dermatitis

Sugimoto K<sup>1\*</sup>, Hattori T<sup>2</sup>, Kitukawa Y<sup>3</sup>, Aotsuka A<sup>3</sup>, Wada T<sup>3</sup>, Kubosawa H<sup>4</sup> and Ito S<sup>5</sup>

<sup>1</sup>Departments of Clinical Allergology, Neurology Clinic Tsudanuma, Funabashi, Japan

<sup>2</sup>Departments of Neurology, Neurology Clinic Tsudanuma, Funabashi, Japan

<sup>3</sup>Departments of Internal Medicine, Chiba Aoba Municipal Hospital, Chiba, Japan

<sup>4</sup>Clinical Pathology, Chiba Aoba Municipal Hospital, Chiba, Japan

<sup>5</sup>Department of Neurology, Chiba University Graduate School of Medicine, Chiba, Japan

\*Corresponding author: Sugimoto K, Departments of Clinical Allergology, Neurology Clinic Tsudanuma, Funabashi, Japan, E-mail: ka.sugimoto.chiba.jp@nifty.com

Received date: August 8, 2018; Accepted date: August 18, 2018; Published date: August 25, 2018

Copyright: ©2018 Sugimoto K, et al. This is an open-access article distributed under the terms of the Creative Commons Attribution License, which permits unrestricted use, distribution, and reproduction in any medium, provided the original author and source are credited.

## Abstract

We acknowledged that many patients suffering from atopic dermatitis had not only disorders of the skin, but also high rates of duodenitis and cervical spine disorders. In addition, we experienced many patients with atopic dermatitis who had duodenitis and cervical spine disorders in the same case. We have proposed treatment combined with treatment using disinfectant into consideration as a countermeasure against *Staphylococcus aureus* that produces many toxins (named superantigen) for general treatment for patients with atopic dermatitis. As a result of treatment proposed by us for the case of atopic dermatitis, the damage of skin rash, duodenum and cervical vertebrae was also improved, and as a result, improvement of allergic test values were obtained in many atopic dermatitis. Therefore, we would like to proceed with the combined use of disinfectant as a countermeasure against *S. aureus* producing superantigens for general treatment in the treatment of atopic dermatitis.

**Keywords:** Atopic dermatitis; Superantigen; Disinfectants; S.aureus; Cytokines

## Introduction

Atopic dermatitis is a disease whose main lesion is pruritus with repeated exacerbations and remissions, and it is defined that many patients have atopic predisposition. Many factors are involved in exacerbation and remission. Kobayashi et al. [1] reported that *Staphylococcus aureus* is involved in the onset and exacerbation of atopic dermatitis. We thought that the involvement of *S. aureus* is particularly important among the many factors involved in exacerbation and remission. We have been advocating Staphylococcal disinfection skin care method using 10% povidone-iodine solution for the treatment of atopic dermatitis since 1997 [2]. By the way, there is a present situation that bacteria etc adhere to the skin eruption of a patient with atopic dermatitis because the barrier mechanism does not have a normal function. It is also proved that migration and phagocytosis of neutrophils of patients with atopic dermatitis are poor and are more susceptible to infection than healthy subjects [3-6]. There are many papers that frequently detect *S. aureus* from the skin of patients with moderate or more severe atopic dermatitis. In the United States already bleach bath therapy has been incorporated into treatment guidelines already. *S. aureus* also produces toxins, and the produced toxin produces a huge amount of cytokines and causes tissue damage, so the toxin is named superantigen [7,8]. So we would like to think about treatment of atopic dermatitis again from our report so far.

## Objects

We asked the first 10 or so patients with atopic dermatitis to undergo duodenal biopsy by gastric cameras and neurological examination and we did the examination etc. after getting consent.

However, after confirming duodenitis and disturbance of cervical vertebrae in many patients with atopic dermatitis, we had examined such tests on patients who hope such tests. We also examined the detection of toxins from *S. aureus* detected from the skin of atopic dermatitis patients using PCR method.

## Results

With the consent of patients and parents for one patient with atopic dermatitis, we would start treatment to wash away 10% povidone-iodine solution on the skin lesions in addition to general treatment. Due to patient's pain due to irritation of 10% povidone-iodine solution, we could not use the stock solution of 10% povidone-iodine, we first diluted 10% povidone-iodine solution and we could start and continue our treatment. We experienced for the first time that improvement of symptoms and skin lesions can be obtained in a short period of time. Therefore, we tried this treatment method to many cases. In experiencing many cases of atopic dermatitis, we experienced not only symptomatic improvement but also dramatic improvement of IgE value and various reagin antibodies in many cases. By the way Yamada and colleagues [9] report that lesions are found in the colon of patients with atopic dermatitis. Kira et al. [10] have reported that patients with atopic dermatitis have cervical myelitis. Kino et al. [11] have reported that patients with atopic dermatitis of infants demonstrated ileal lesions with echogenic findings and that ileal lesions improved with skin lesions improvement. So we got consent from patients with atopic dermatitis and inspected many cases for lesions such as duodenum and cervical vertebrae. We have reported some of these results up to now. [12-15] We were able to experience many cases of patients with atopic dermatitis who had duodenitis and disorders of cervical spine in the same case. Ito et al examined the disturbance of the cervical vertebrae of patients with atopic dermatitis and as a result reported that atopic dermatitis is a risk factor causing

cervical spine degeneration [16]. In addition, toxin was detected in more than 80% from *S. aureus* obtained from the skin of patients with atopic dermatitis. Since toxin produces a huge amount of cytokines, it is named superantigen and it has been reported that the cytokine causes tissue damage. Therefore we proposed that atopic dermatitis is one of the superantigens diseases [17-21].

### A Case of Recently Experienced Atopic Dermatitis

We will present a case of atopic dermatitis at the age of 41 at the first visit. The serum TARC value at the first visit was very high at 28803 PG/mL and at the treatment day 7 it was halved to 14850 PG/mL. Serum IgE value increased slightly from 3879 IU/mL to 4478 IU/mL in 7 days, and the serum anti-SEA IgE antibody titer (Figure 1) was almost unchanged at 0.58 IU/mL and 0.59 IU/mL. TARC was 2896 PG/mL, IgE value was 4303 IU/mL and anti-SEA IgE antibody titer was 0.74 IU/mL in the third examination at the second month of treatment. Thus, the TARC values and IgE values were dramatically improved over time from the start of treatment. In the second and third tests, the IgE value and the anti-SEA IgE antibody titer were somewhat higher than the first. It is very interesting that the inspection values will improve so much in a short period of time. We speculate that *S. aureus* was stimulated with a disinfectant and, as a result, produced toxins in large quantities. We had reported that the IgE value and the anti-SEA IgE antibody titer would change in many cases concurrently with the improvement of the skin lesions from 2 months after the treatment.

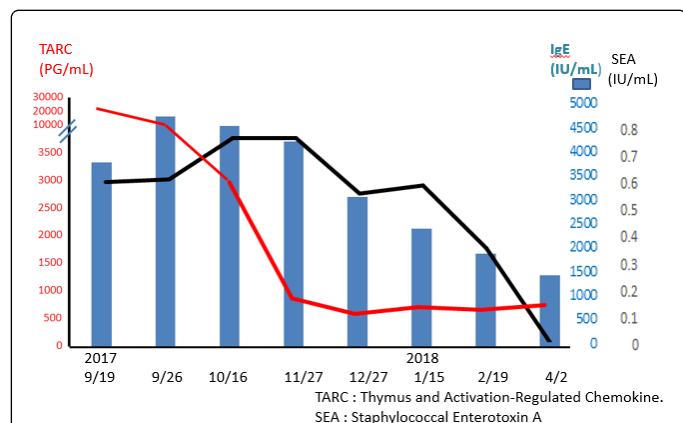


Figure 1: Changes in allergic tests from the start of disinfection therapy

### Discussion

Atopic dermatitis is a chronically progressive disease and it is difficult to recover completely even if it is hard to treat. There was no treatment considering *S. aureus* in the general treatment so far. It takes about 27 minutes for binary division of *S. aureus*. Bleach bath therapy in the United States is thought to be treatment which considered *S. aureus* in it. However, it is difficult to conduct bleach bath therapy every day, so it is impossible to completely sterilize *S. aureus*. The disinfection skin care method of *S. aureus* using our 10% povidone-iodine solution can be done twice to four times a day. It is not necessary to worry about absorption of iodine from the skin by washing away after applying the 10% povidone-iodine solution in a few minutes. There is also remarkable improvement in rash by adding it to

general treatment. Because improvement of skin rash is remarkable, it is not necessary to perform this treatment for a long period of time, and worry of contact dermatitis is reduced.

### Conclusion

We observed in patients with atopic dermatitis not only lesions of the skin but also duodenitis and disorders of cervical spine in many cases. Moreover, we experienced patients with many atopic dermatitis who had duodenitis and disturbance of cervical spine in the same case. We reported that *S. aureus* detected from the skin of patients with atopic dermatitis produces toxins in more than 80%. *S. aureus* produces toxin at a high rate, and its toxin is named superantigen by producing super-massive cytokines and causing tissue damage. Therefore, we proposed that atopic dermatitis is one of superantigen diseases. In the future, we hope for treatment of atopic dermatitis, considering disinfectant as a countermeasure against *S. aureus*, taking into account that atopic dermatitis is a superantigen.

### References

- Kobayashi T, Glatz M, Horiuchi K, Kawasaki H, Akiyama H, et al. (2015) Dysbiosis and Staphylococcus aureus Colonization Drives Inflammation in Atopic Dermatitis. J Immunology 42: 756-766.
- Sugimoto K, Kuroki H, Kanazawa M, Kurosaki T, Abe H, et al. (1997) New successful treatment with disinfectant for atopic dermatitis. Dermatol 195: 62-68.
- Imayama S, Shimozono Y, Hoashi M, Yasumoto S, Ohta S, et al. (1994) Reduced secretion of immunoglobulin-A to the skin surface of patients with atopic dermatitis. J Allergy Clin Immunol 94: 195-200.
- Ternowitz T, Herlin T (1986) Defective monocyte and polymorphonuclear leukocyte chemotaxis and clinical characteristics in atopic dermatitis. Arch Dermatol Res 278: 454-459.
- Schöpf E, Kapp A (1987) Chemiluminescence Response of Polymorphonuclear Leukocytes in Atopic Dermatitis. Int Arch Allergy Appl Immunol 82: 380-382.
- Hoeger PH, Niggemann B, Schroeder C (1992) Enhanced basal and stimulated PMN chemiluminescence activity in children with atopic dermatitis: stimulatory role of colonizing staphylococci? Acta Paediatr 81: 542-546.
- White J, Herman A, Pullen AM, Kubo R, Kappler JW, et al. (1989) The V beta-specific superantigen staphylococcal enterotoxin B: stimulation of mature T cells and clonal detection in neonatal mice. Cell 56: 17-35.
- Ochi H, Osoegawa M, Murai H, Minohara M, Taniwaki T, et al. (2004) Presence of IgE Antibodies to Bacterial Superantigens and Increased IL-13-Producing T Cells in Myelitic Patients with Atopic Diathesis. Int Arch Allergy Immunol 134: 41-48.
- Yamada H, Izutani R, Chihara J, Yudate T, Matsukura M, et al. (1996) RANTES mRNA expression in skin and colon of patients with atopic dermatitis. Int Arch Allergy Immunol 111: 19-21.
- Kino M, Kojima T, Yamamoto A, Sasal M (2002) Bowel wall thickening in infants with food allergy. Pediatr Radiol 32: 31-33.
- Kira J, Yamasaki K, Kawano Y, Kobayashi T (1997) Acute myelitis associated hyperIgEemia and atopic dermatitis. J Neurol Sci 148: 199-203.
- Sugimoto K, Ishikawa N, Sugioka T (1998) Isojin® disinfectant therapy for atopic dermatitis. Japanese J Pediatric Dermatol 17: 103-107.
- Sugimoto K, Ishikawa N, Ogawa A (1998) Treatment of Staphylococcus aureus by disinfection treatment of patients with atopic dermatitis. Hifu 40: 117-124.
- Sugimoto K, Ishikawa N, Sugioka T, Koseki H, Kubosawa H, et al. (2002) The importance of disinfection therapy using povidone-iodine solution in atopic dermatitis. Dermatology 204: 63-69.
- Sugimoto K, Ishikawa N, Terano T, Kitukawa Y, Kubosawa H, et al. (2006) The importance of Bacterial Superantigens Produced by Staphylococcus

- 
- aureus in the Treatment of Atopic Dermatitis Using Povidone-Iodine. Dermatology 212: 26-34.
16. Ito S, Hattori T, Fukutake T, Sugimoto K (2003) Is atopic dermatitis a risk factor for intervertebral disc degeneration? A preliminary clinical and MRI study. J Neurol Sci 206: 39-42.
17. Sugimoto K, Kitukawa Y, Aotsuka A, Wada T, Kubosawa H, et al. (2015) Is Atopic Dermatitis One of the Superantigen Diseases?. J Dermatolog Clin Res 3: 1052-1053.
18. Sugimoto K (2016) Staphylococcus aureus vs. Atopic Dermatitis. J Pharm Microbiol 2: 1-3.
19. Sugimoto K, Hattori T, Kitukawa Y, Aotsuka A, Wada T, et al. (2016) The Treatment of Symptoms in Atopic Dermatitis as a Superantigen Disease. J Microbiol Mod Tech 1: 1-3.
20. Sugimoto K, Kitukawa Y, Aotsuka A, Wada T, Kubosawa H, et al. (2016) Evaluation of disinfection therapy for atopic dermatitis. Int J Clin Expl Dermatol 1: 1-3.
21. Sugimoto K, Hattori T, Kitukawa Y, Aotsuka A, Wada T, et al. (2017) Importance of Measures against *Staphylococcus aureus* in Atopic Dermatitis as a Superantigen Disease. Sci J Clin Res Dermatol 2: 007-009.